

# Acanthomatous Ameloblastoma mimicking Carcinoma: A Case Report with Review

Supriya Mohit Kheur<sup>1</sup>, Deepali Yogesh Patekar<sup>2</sup>,  
Praveen More<sup>3</sup>, Amit Sangle<sup>4</sup>



doi: 10.5866/2014.641720

<sup>1</sup>Professor and Head

<sup>3</sup>PG Student

Department of Oral Pathology,  
Dr. D.Y.Patil Dental College & Hospital,  
DPU, Pimpri, Pune, India

<sup>2</sup>Lecturer

Saraswati-Dhanwantari Dental College & Hospital &  
Post Graduate Research Institute  
Dr. Prafulla Patil Educational & Hospital Campus,  
Parbhani - 431 401 (M.S.) INDIA

<sup>4</sup>Professor

Dept of oral & Maxillofacial Surgery,  
M.A. Rangoowala College of Dental Sciences &  
Research Centre Pune.

## Article Info:

Received: July 7, 2014

Review Completed: August 8, 2014

Accepted: November 10, 2014

Available Online: January, 2015 (www.nacd.in)

© NAD, 2015 - All rights reserved

## Email for correspondence:

supriya.kheur@dpu.edu.in

## INTRODUCTION

Of the odontogenic tumors that are thought to be true neoplasm, the ameloblastoma is the most common. In a large series reviewed by Small and Waldran (1955), ameloblastoma represented about

1% of all cysts and tumours of the jaw.<sup>1</sup> This was described first time by Broca (1868) as Adamantinoma and then recoined by Churchill (1934).<sup>2</sup> In 2005 WHO classified ameloblastoma into 4 types: 1) Solid/Multicystic 2) Desmoplastic 3) Unicystic 4) Extraosseous/Peripheral types.<sup>3</sup>

## ABSTRACT:

Ameloblastoma is second most common intraosseous benign tumor of odontogenic epithelium more commonly appearing in the lower jaw than the upper jaw. This tumor exhibits a locally aggressive behavior. The term acanthomatous ameloblastoma refers to extensive squamous metaplasia, often associated with keratin formation occurs in central portions of the epithelial islands of follicular ameloblastoma. Here a unique case of verrucous growth of the surface epithelium, in habit associated individual, in which the intraosseous component turned out to be acanthomatous ameloblastoma is presented.

**Key words:** Acanthomatous ameloblastoma, squamous metaplasia, keratin pearl, verrucous carcinoma.

Ameloblastoma is a locally aggressive neoplasm of odontogenic epithelium that has a wide spectrum of histologic patterns resembling early odontogenesis. Histologically commonest types of ameloblastomas are Follicular and Plexiform. The uncommon variants are Acanthomatous, Granular, Desmoplastic, Basal cell and Clear cell.<sup>5</sup>

In acanthomatous type the central area of follicles often undergo squamous metaplasia with the development of intercellular bridges and keratinisation. This can be florid occasionally to the point where so much of the lesion is replaced by squamous cells that it may resemble a squamous cell carcinoma.<sup>6</sup>

Krishna et al studied protein over expression (MDM2) in ameloblastoma and oral squamous cell carcinoma (OSCC) and found that the keratinizing cells of acanthomatous ameloblastoma showed less MDM2 reactivity as compared to high reactivity in OSCC which could be suggestive of terminal differentiation and non-proliferative phenotype of central cells.<sup>7</sup>

Here we report a rare case of acanthomatous ameloblastoma with surface epithelium showing verrucous changes in 55 year old healthy female with mild swelling in left lower anterior jaw between canine and premolar area.

### Case report

A 55 year old female patient came to our institution with a chief complaint of swelling in the lower left anterior jaw region since 5-6 months which was initially small in size and gradually increased to the present size. Intra orally there was a single small swelling in canine premolar area of lower left buccal gingival and alveolus with expansion of cortical plates leading to displacement of premolars. The swelling was approximately 1.5 x 1.5 cm and extended from distal area of incisor to first premolar. The overlying mucosa was whitish in color, rough and verrucous in appearance (Figure 1). On enquiring regarding personal history patient had habit of applying mishri (roasted tobacco) 6-8 times a day since 10 years. On clinical appearance we gave provisional diagnosis as Verrucous carcinoma.

An orthopantomogram (OPG) showed radiolucent area extending from lateral incisor to first premolar area with expansion of cortical plates without any resorption of roots (Figure 2).

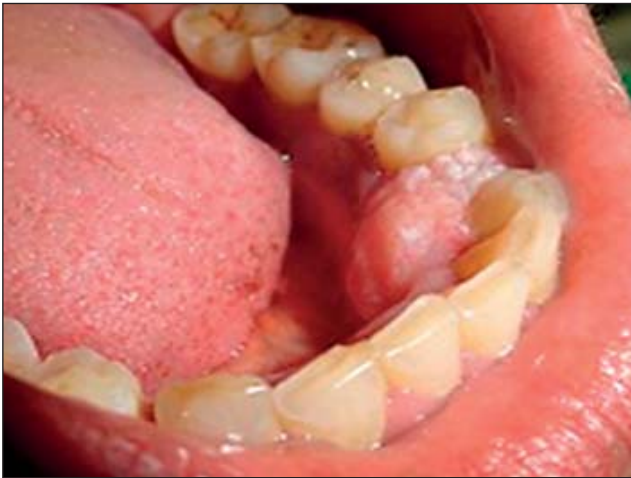The hematoxylin and eosin (H & E) stained lesional tissue was composed of follicles lined by tall columnar cells and filled with central stellate reticulum like cells suggestive of ameloblastic follicles. Many of them showed squamous metaplasia and cystic degeneration. Overlying epithelium showed characteristic features of verrucous carcinoma. Surface epithelium was proliferative stratified squamous type with broad bulbous rete pegs. Epithelium showed elephant like rete pegs merging with ameloblastic follicles (Figure 3-5). Thus, the clinical and histopathological features were consistent with the diagnosis of verrucous carcinoma. But, the underlying bony invasion was due to proliferation of the ameloblastic follicles. All three entities were seen: epithelial proliferation, normal stroma and ameloblastic follicles. Thus, after histopathological evaluation a final diagnosis as acanthomatous ameloblastoma with verrucous epithelial proliferation was made.

### Discussion

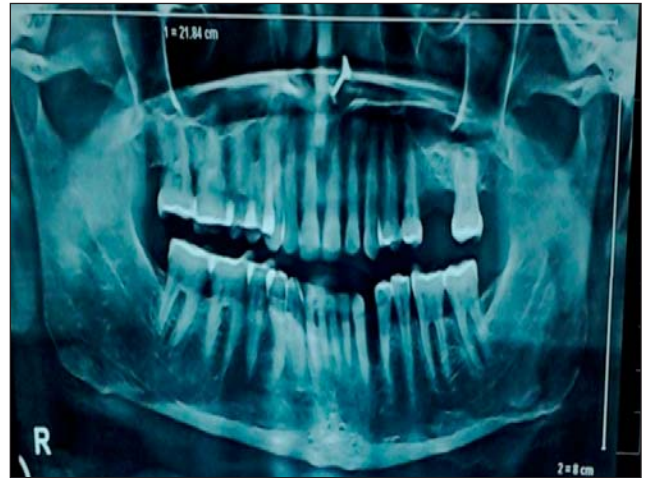Acanthomatous ameloblastoma is a rare variant with distinctive features which accounts for 12.1% of cases.<sup>8</sup> Ameloblastoma carry a certain risk of developing local recurrences depending on two main factors i.e., its histologic subtypes and type of surgical treatment.<sup>9</sup> Considering the histologically, keratinization in ameloblastoma is found only in 3 variations: Acanthomatous ameloblastoma, Keratoameloblastoma and Papilliferous ameloblastoma.<sup>10</sup> In acanthomatous ameloblastoma islands of odontogenic epithelium exhibiting peripheral nuclear palisading with reverse polarization and conspicuous central squamous differentiation is seen. Squamous metaplasia such as that seen in acanthomatous ameloblastoma may be attributed to chronic irritation, calculus and oral sepsis (which could be a source of chronic irritation) have been suggested to play a role in etiology of ameloblastoma.<sup>11</sup>

In keratoameloblastoma simultaneous occurrence of areas of ameloblastoma with active production of parakeratin and cystic areas resembling odontogenic keratocysts are noted. Keratoameloblastoma fall into four groups: 1) papilliferous histology 2) simple histology 3) simple histology with odontogenic keratocyst (OKC)-like features (4) complex histology.<sup>12</sup> In papilliferous ameloblastoma in addition to keratoameloblastoma,

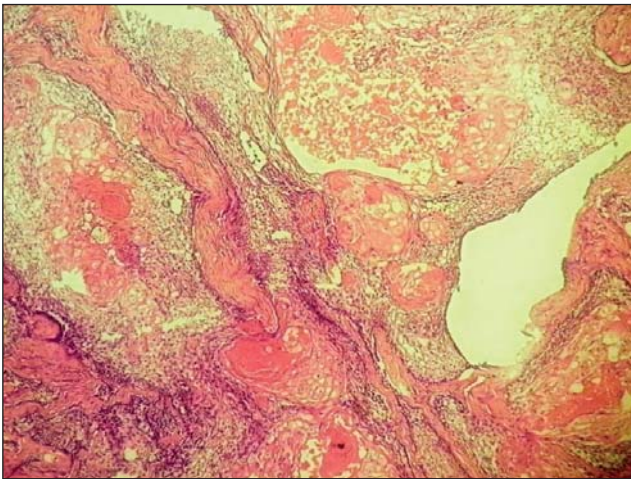




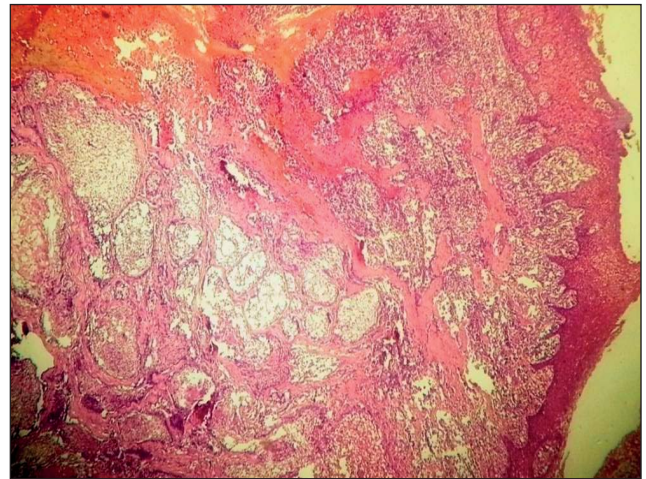
**Figure 1:** Intra oral photograph showing 1.5 x 1.5 cm swelling between 33 and 34 and verrucous whitish appearance interdentally



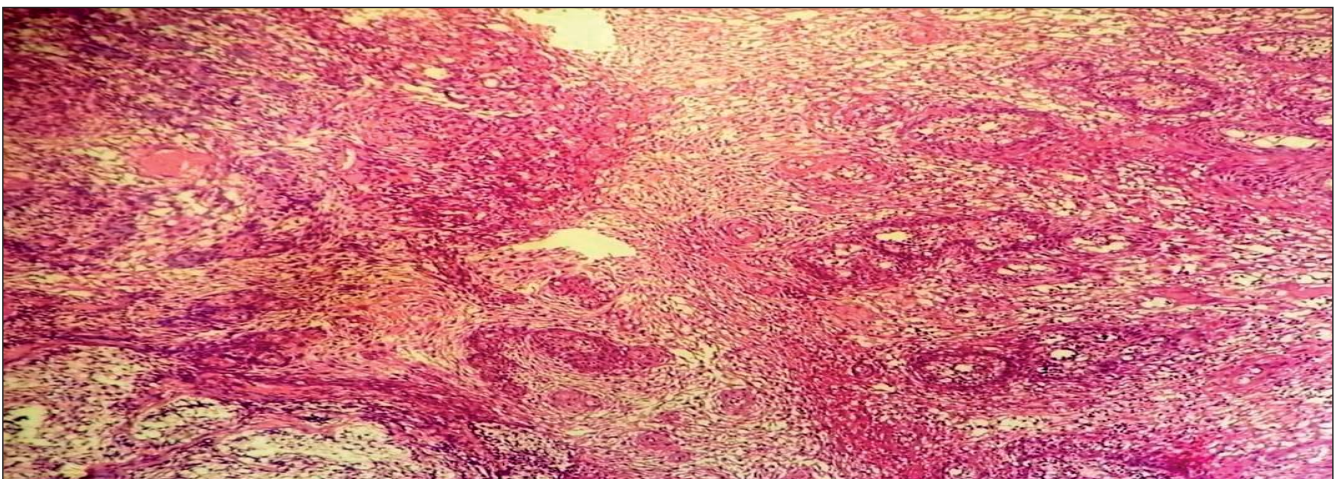
**Figure 2:** OPG reveals osteolytic lesion between 33 and 34



**Figure 3:** H and E stained section shows squamous metaplasia in ameloblastic follicles, acanthomatous ameloblastomas



**Figure 4:** H and E stained section shows verrucous proliferation of overlying epithelium and concomitant ameloblastic follicles



**Figure 5:** H and E stained section of low power view exhibiting "pulling in" of the surface epithelium



the cystic epithelium resembles proliferation in papillary appearance.<sup>11,12</sup>

Some authorities believe that acanthomatous ameloblastoma if left untreated can develop into an invading squamous cell carcinoma. It is important to note in these circumstances, however, that metaplasia of the odontogenic epithelium toward the squamous cell type in acanthomatous ameloblastoma can simulate the appearance of both a squamous cell carcinoma and a basal cell carcinoma.<sup>13</sup>

The suggestive treatment is surgery, with wide resection recommended due to the high recurrence rate of solid/multicystic ameloblastomas. The recurrence rate after resection is 13-15%, as opposed to 90-100% after curettage. It is recommended that a margin of 1.5-2 cm beyond the radiological limit to ensure all microcysts is removed. Several studies suggest treatment as an important prognostic factor, specifically implicating under treatment as a cause of recurrence.<sup>14</sup> But, if the lesion is treated as verrucous carcinoma, then a more extensive surgery would be required.<sup>15</sup> Considering osteolytic or bony invasion was due to the ameloblastic follicles it is apt to treat the lesion as acanthomatous ameloblastoma with conservative approach. The present case describes the clinical confusion that can arise due to the surface epithelium involvement in ameloblastoma.

### Conclusion

Patients generally present with a slow growing expansile lesion, loose teeth, with pain or malocclusion or paresthesia in case of Ameloblastomas. This is a unique case in which there were no other clinical symptoms present other than just proliferative epithelial growth mimicking verrucous carcinoma. As, the patient was giving history of tobacco abuse, it was more indicative of epithelial malignancy rather than odontogenic lesion. Thus, this case re-emphasizing the need for

thorough clinical and histopathological diagnosis as clinical variation alone can lead to misdiagnosis and subsequently altered treatment for the patient.

### REFERENCES

1. Prabhu S, Wilson D, Daftary D, Johnson N. Oral diseases in the tropics. In: Smith C (ed) Odontogenic neoplasm and hamartomas, 1<sup>st</sup> edn. Oxford university press, Delhi, 1993; pg 369.
2. Bansal M, Chaturvedi TP, Bansal R, kumar M. Acanthomatous ameloblastoma of anterior maxilla. J Indian Soc Pedod Prev Dent 2010; **28**(3):209-211.
3. Khaled S, Mirdza N, Frank C, Alfredo A. Morphological variants of ameloblastoma and their mimickers. N A J Med Sci 2012; **5**(1):20-28.
4. Sapp J, Eversole L, Wysocki G. Contemporary oral and maxillofacial pathology. In: Odontogenic tumors, 2<sup>nd</sup> edn. Mosby, China, 2004; pg136.
5. Ankur B, Sonal S, Monali C. Acanthomatous ameloblastoma of mandible. J Dent Sci Res 2011; **2**(2):1-5.
6. John W E, Crispian S. Colour atlas of oral pathology. In: Odontogenic tumor, 1<sup>st</sup> edn. Mosby-Wolfe, Barcelona, 1995;pp 43.
7. Krishna K, Kaveri H, Naveen RK et al. Overexpression of MDM2 protein in ameloblastomas as compared to adenomatoid odontogenic tumor. J Cancer Res Ther 2012; **8**:232-237.
8. Reichart PA, Philipsen HP, Sonner S. Ameloblastoma: biological profile of 3677 cases. Eur J Cancer B Oral Oncol 1995; **31**(2):86-99.
9. C Mohammadinezhad, AM Aarabi, B Zamiri. Recurrent ameloblastoma of the ameloblastoma of the the mandible: two cases report. Iranian Red Crescent Med J 2009; **11**(3):340-343.
10. Adeyemi BF, Adisa AO, Fasola AO, Akaang EE. Keratoameloblastoma of the mandible. JOMFP 2010; **14**(2):77-79.
11. Stolf DP, Algernon CK, Banerjee AG. Genetic aspects of ameloblastoma: A brief review. Biotechnol Molecular Biol Rev 2007; **2**:116-122.
12. Altini M, Slabbert HD, Johnston T. Papilliferous keratoameloblastoma. J Oral Pathol Med 1991; **20**(1):46-48.
13. Anneroth G, Anders H, Jan W. Acanthomatous ameloblastoma. Int. J Oral Surg 1980; **9**:231-236.
14. Chappelle KAOM, Stoelinga PJW, de Wilde PCM, Brouns JJA, Voorsmit RACA. Rational approach to diagnosis and treatment of ameloblastomas and odontogenic keratocysts. Br J Oral Maxillofac Surg 2004; **42**:381-390.
15. Sciubba JJ, Helman JI. Current management strategies for verrucous hyperkeratosis and verrucous carcinoma. Oral Maxillofac Surg Clin North Am 2013; **25**(1):77-82.

Gain quick access to our journal online  
View our journal at [www.nacd.in](http://www.nacd.in)